

Rosacea: seeing red in primary care

Rosacea is an inflammatory facial skin disease that can cause patients embarrassment and reduce their quality of life. There are several different subtypes of rosacea and multiple treatments may be required to achieve satisfactory symptom relief. Topical treatments are first-line with oral treatments reserved for patients with persistent and severe rosacea. It should be noted that there is a lack of subsidised topical treatments and oral treatments that are subsidised are “off-label”.

Rosacea is often encountered but is poorly understood

Rosacea is an inflammatory facial skin disease characterised by flushing, redness, papules, pustules and telangiectasia (permanent dilation of small blood vessels).^{1, 2} A person's cheeks, chin, forehead and nose are typically affected while peri-oral and peri-orbital areas are often spared.² Rosacea may be transient, recurrent or persistent.¹ In the past the condition was sometimes referred to as acne rosacea, however, rosacea is unrelated to acne vulgaris.¹

New Zealand data on the prevalence of rosacea is lacking. Worldwide estimates of prevalence vary from less than 1% to

22% depending on the population and the definition used.^{2, 3} Rosacea is often encountered in people of Celtic descent with blue eyes and fair skin,¹ leading to the expression “the curse of the Celts”. Rosacea may also occur in Māori, Pacific and Asian people. A study in the United States suggests that people with white skin are twice as likely to present to a health provider and be diagnosed with rosacea as people of Pacific Island or Asian ethnicity.⁴ Rosacea is most frequently diagnosed in people aged 40 – 59 years and is rare in people aged under 30 years.³

There are four subtypes of rosacea (see: “The subtypes of rosacea”) which may respond differently to treatment. Patients with rosacea often have more than one subtype and may require multiple treatments.⁵

The pathophysiology of rosacea

Multiple factors are known to contribute to the development of rosacea. A genetic cause¹ has not been found, although genes involved in both the innate and adaptive immune system appear to be involved in overactive immune signalling.⁶ High levels of cathelicidins are often present in patients with rosacea.¹ These antimicrobial peptides, which are part of the innate immune system, promote neutrophilic infiltration of the dermis and dilation of blood vessels causing oedema and further inflammation.¹

The subtypes of rosacea

There are four subtypes of rosacea. These subtypes do not represent progressive stages of the disease and patients may develop multiple subtypes at the same time. Concurrent seborrhoeic dermatitis is often present, which can make diagnosis difficult.

Erythematotelangiectatic rosacea features flushing and persistent facial erythema, with or without telangiectasia (Figure 1). Patients are typically unaffected in periorbital areas but are likely to have a history of flushing and may also have central facial oedema, a sensation of stinging or burning and rough or scaly skin.

Papulopustular rosacea features transient papules or pustules (Figure 2) which may occur in peri-oral, perinasal or peri-ocular areas. Papulopustular rosacea and

erythematotelangiectatic rosacea may occur together. Telangiectasia can be present, but this is often obscured by erythema and pustules. This subtype may be confused with acne vulgaris, which may occur concurrently, particularly in younger patients.

Phymatous rosacea features thickened skin and irregular surface nodules. Changes to the nose are the most prevalent feature, i.e. rhinophyma (Figure 3), but phymatous rosacea can occur on the person's chin, forehead, cheeks and ears. Phymatous rosacea is often seen in combination with the erythematotelangiectatic and papulopustular rosacea subtypes.

Ocular rosacea (Figure 4) is characterised by inflammation of the eyelid and the eye, which may include the conjunctiva and cornea, and rarely the iris and sclera.^{5,10}

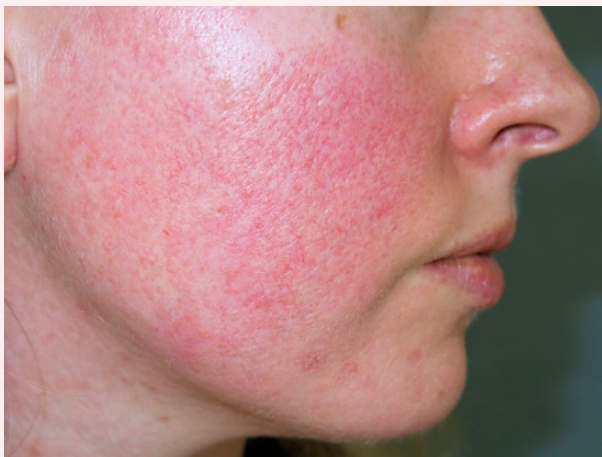

Figure 1: Telangiectasia

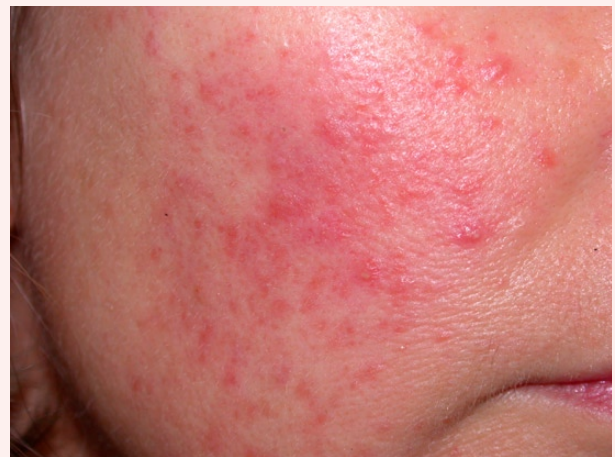

Figure 2: Mild papules and pustules

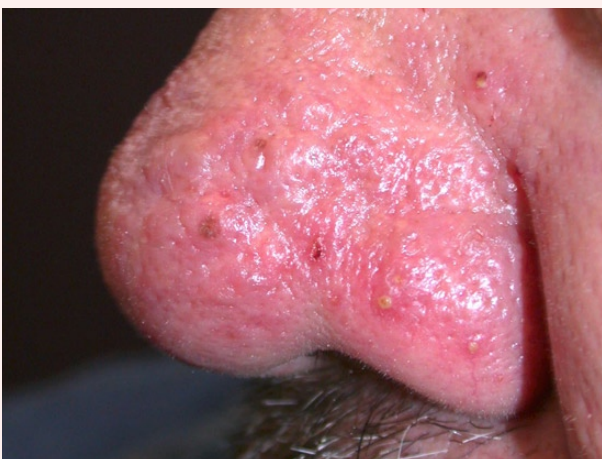

Figure 3: Early rhinophyma and inflammatory papules

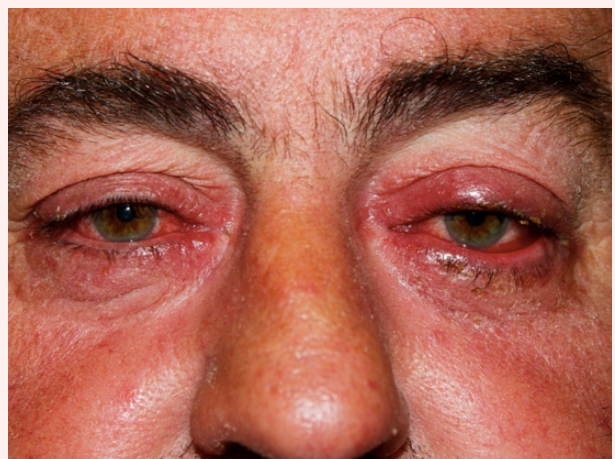

Figure 4: Ocular rosacea

Ultraviolet (UV) radiation worsens the symptoms of rosacea as it has a pro-inflammatory effect on skin. UVA light causes collagen denaturation and activates the inflammatory cascade.⁶ UVB light increases the expression of fibroblast and vascular growth factors, which promote skin hypervascularity.⁶ High levels of matrix metalloproteinases (MMPs), such as collagenase and elastase, may also contribute to inflammation and the thickened, harder skin of people with rosacea through tissue remodelling.¹ MMPs have also been implicated in the loss of dopaminergic neurons and it has been reported that rosacea is an independent risk factor for Parkinson's disease.⁷

Hypersensitive receptors in the skin may also be stimulated by factors such as heat or capsaicin in foods and exacerbate flushing and burning.⁶ Increased water loss across the epithelium and decreased epidermal hydration may contribute to the pathogenesis of rosacea by reducing the skin's barrier function.⁶

The microbiology of rosacea

People with rosacea have increased counts of *Staphylococcus epidermidis* and the hair follicle mite *Demodex folliculorum*. These organisms stimulate skin pathogen receptors, which increase inflammation.⁶ *Bacillus oleronius* has also been linked to rosacea, probably due to increased inflammatory cytokine production.⁶

Helicobacter pylori may be associated with the development of rosacea, as there is a high prevalence of the bacterium in the gastrointestinal tract of patients with rosacea.⁸ *H. pylori* can increase levels of nitrous oxide in the blood or tissues which may contribute to erythema.⁸

The symptoms of rosacea can cause psychological issues

People with rosacea often have dry, flaky, sensitive skin that may burn or sting when facial creams, e.g. sunscreen or make-up, are applied.¹ They may also experience blepharitis, sore and inflamed eyes, swelling of facial areas and a subgroup of patients develop an enlarged nose (rhinophyma) with prominent pores (sebaceous hyperplasia).¹ Rosacea can result in embarrassment, social anxiety and depression.⁹

A diagnosis of rosacea is based on symptoms and signs

A diagnosis of rosacea can be made clinically in patients with characteristic symptoms and signs and investigations are not usually required.¹ If there is uncertainty a skin biopsy may be performed with long-term inflammation and vascular changes consistent with a diagnosis of rosacea.¹

The patient's history may reveal triggers that may be avoided as well as identifying the symptoms that the patient finds most bothersome, in order to guide treatment.

Erythema, pustules and telangiectasia are the primary symptoms

Patients with rosacea often initially develop temporary facial flushing similar to a blush or sunburn in the centre of the face due to vasodilation. This erythema gradually becomes more noticeable and permanent, with the development of swelling. A diagnosis of rosacea requires one or more of the following primary symptoms:¹

- Transient erythema, i.e. flushing
- Non-transient erythema
- Telangiectasia (Figure 1)
- Papules or pustules (Figure 2)

Secondary features that that can assist in the diagnosis include a burning or stinging sensation, dry skin, oedema, phymatous changes, i.e. thickened skin, nodularities and rhinophyma, and ocular symptoms.⁶

Ocular rosacea is often present

Many people with rosacea will also have signs of ocular rosacea (Figure 4).⁵ This may cause watery or bloodshot eyes, blurred vision, light sensitivity, dry eyes, burning, stinging or itchy eyes as well as being prone to recurrent hordeolum (stye).⁵ Conjunctivitis, anterior blepharitis including irregularities of the eyelash bases and eyelid margin, and posterior blepharitis effecting ducts and eye secretions, and meibomian cysts (chalazia) may also be present.^{5,10} Symptoms of more severe ocular rosacea may include keratitis, iritis, episcleritis and scleritis.⁵

Differential diagnoses to consider

Dermatological conditions with symptoms and signs similar to rosacea include:¹

- Acne vulgaris
- Rosacea fulminans
- Contact dermatitis
- Steroid rosacea
- Perioral or periorificial dermatitis
- Seborrhoeic dermatitis

The patient's age, history and symptoms are helpful when considering the possibility of other dermatological conditions. New onset acne vulgaris is uncommon in older patients. The presence of open and closed comedones (blackheads and whiteheads) makes a diagnosis of acne vulgaris more likely, as these are not a feature of rosacea.¹ Rosacea fulminans occurs more often in young adult females and may resemble rosacea or severe acne, but it is not associated with flushing. A recent

history of topical steroids or thick emollient use is consistent with steroid rosacea. An irregular distribution and recurrent episodes of blistering with swelling, or red, dry plaques may indicate contact dermatitis. Seborrhoeic dermatitis and perioral/periorificial dermatitis often affect other areas of the patient's skin and are not associated with facial flushing.

The treatment of rosacea

The three components of rosacea treatment are:¹¹

1. Patient education and advice
2. Pharmacological treatment
3. Follow-up and referral as required

The goal of management is to improve the quality of life of patients by alleviating problematic symptoms;⁹ multiple long-term treatment strategies may be necessary to achieve this. Patient satisfaction is used to assess treatment efficacy as there are no validated assessment tools available.

Patient education and advice

Effective communication can improve the well-being and quality of life of people with rosacea.¹¹ It is important to set realistic treatment goals.


Patients can be encouraged to keep a diary to identify triggers, which may include:¹¹

- Sunlight
- Temperature extremes
- Wind
- Spicy foods
- Hot drinks; due to temperature rather than caffeine¹²
- Alcohol
- Stress
- Medicines, e.g. topical corticosteroids, nicotinic acid and other vasodilators

Reducing triggers and protecting facial skin are important aspects of management, particularly as many of the pharmacological treatments for rosacea are unsubsidised and/or unapproved. Patients can be advised to:¹

- Regularly use moisturisers, e.g. non-greasy emollients, to reduce moisture loss and improve skin texture, if dry
- Wear a hat and apply sunscreen or sunscreen containing moisturiser when outdoors
- Reduce exposure to spicy foods, alcohol and hot showers
- Place ice between the cheek and gum for the short-term reduction of erythema
- Manage blepharitis from ocular rosacea through:¹⁰
 - Warm compression and gentle massage of the eyelid margin

- Cleaning the eyelid with a cotton bud or along the eyelid margin with dilute baby shampoo
- The avoidance of cosmetics around the eye, particularly eyeliner
- Using preservative-free ocular lubricants to treat dry eyes

 For further information on blepharitis, see: "Causes, complications and treatment of a red eye", BPJ 54 (Aug, 2013).

The pharmacological treatment of rosacea

Topical treatments are appropriate for mild rosacea and these should, ideally, be trialled first and oral treatments reserved for patients with moderate to severe rosacea.

Topical treatments for rosacea

Head-to-head studies have been unable to determine whether topical metronidazole or topical azelaic acid is more effective for the treatment of rosacea.⁵

Metronidazole cream (0.75%) or gel (0.5%, 0.75%) is the approved but unsubsidised topical treatment option for people in New Zealand with rosacea.¹ The effectiveness of metronidazole is due to its anti-inflammatory properties, rather than antimicrobial effects, and it may be used intermittently, long-term or in combination with oral treatments (see below) for more severe cases.¹¹


Apply topical metronidazole widely to affected areas of skin, twice daily, for three to four months.¹³ An improvement in symptoms can be expected after three to six weeks of treatment,⁵ and remission of symptoms may last for six months.¹¹

Adverse effects due to topical metronidazole may include dry and mildly irritated skin, but generally both cream and gel are well tolerated.^{5, 14}

Azelaic acid is an alternative topical anti-inflammatory medicine which is unsubsidised and unapproved for the treatment of rosacea. Topical azelaic acid is available over-the-counter as a 20% cream or lotion.¹³ Prescribing topical azelaic acid in preference to topical metronidazole may have the benefit of not contributing to antimicrobial resistance.

Azelaic acid is applied once or twice daily, for three to four months, for the treatment of rosacea.^{1, 15} As many as 70–80% of patients with rosacea can expect some degree of symptom improvement three to six weeks after starting treatment with azelaic acid.^{5, 14}

Adverse effects associated with topical azelaic acid may include mild burning, stinging or irritation.^{5, 14}

 **Best Practice point:** Topical corticosteroids are not appropriate for the treatment of rosacea. These medicines

may provide patients with short-term benefits due to their vasoconstrictive and anti-inflammatory properties, but the patient's symptoms are likely to be aggravated over the coming weeks.¹

Two other medicines used to treat patients with rosacea overseas which are not available in New Zealand are:

- Brimonidine gel (0.33%) to reduce redness short-term in erythematous rosacea
- Ivermectin cream can improve papulopustular rosacea

Oral treatments for rosacea

Oral medicines may be appropriate for patients with rosacea that is resistant to topical treatments or for patients with severe rosacea. Non-steroidal anti-inflammatory drugs (NSAIDs), in appropriate patients, may relieve the discomfort and erythema of rosacea.¹

Tetracycline antibiotics are known to interfere with the inflammatory process and can reduce the erythema, papules, pustules and eye symptoms caused by rosacea.¹ These have been shown to be effective at doses lower than required for antimicrobial treatment and therefore produce a clinical benefit for patients via a different mechanism, possibly through the inhibition of metalloproteases.¹⁰

Both oral doxycycline and minocycline (partially subsidised) are effective treatments for patients with rosacea.¹ Low doses of these tetracyclines, e.g. 50 mg daily, are often as beneficial as higher doses, e.g. doxycycline 100–200 mg daily, and are unlikely to contribute to antimicrobial resistance.¹⁶ Repeated courses of tetracyclines may be required.

Recommended initial treatment regimens are:¹³

- Doxycycline 50 mg, once daily, for six to 12 weeks
- Minocycline 50 mg, once daily, for six to 12 weeks

Doxycycline is available in 50 mg tablets (partially subsidised) or 100 mg tablets (fully subsidised).¹³ Doxycycline tablets should not be broken in half as damaging the film coating of the tablet increases the patient's risk of developing oesophagitis;¹⁷ to achieve a lower dose, with the fully subsidised formulation, some dermatologists advise patients to take a 100 mg tablet on alternate days.

Gastrointestinal adverse effects, heartburn, nausea, vomiting and diarrhoea, are most commonly reported following the use of tetracyclines.¹³ Photosensitivity, including photo-oncholysis, may occur in patients taking doxycycline. Advise patients using doxycycline to avoid prolonged exposure to sunlight and artificial sources of UV radiation.¹³ Minocycline is less likely to cause gastrointestinal adverse effects and

photosensitivity, although there is an increased risk of hepatitis and drug-induced lupus erythematosus.

Tetracycline antibiotics are contraindicated in women who are pregnant or breast-feeding.¹³

Oral erythromycin may be prescribed to patients with rosacea as an alternative to oral tetracyclines, as an unapproved indication. The suggested treatment regimen is:¹³

- Erythromycin 400 mg, twice daily, for six to 12 weeks

Low-dose oral isotretinoin is not a first-line treatment but may be considered as an alternative for some patients

if oral antibiotics have been ineffective or are not tolerated.¹ Isotretinoin is not approved in New Zealand for the treatment of rosacea, although there is good evidence to support its use in patients with severe and persistent rosacea and those with papulopustular and phymatous subtypes of rosacea.^{5, 13, 18, 19} Special Authority approval for isotretinoin requires female patients be warned about the teratogenic effects of the medicine and that they use at least one effective form of contraception for one month before, during and one month after treatment has ceased. It is recommended that general practitioners discuss the patient with a dermatologist before initiating isotretinoin for the treatment of rosacea. Patients should not use isotretinoin and tetracyclines concurrently due to an increased risk of benign intracranial hypertension.²⁰

The recommended treatment regimen is:⁵

- Isotretinoin, 0.1 – 0.3 mg/kg/day for 12 weeks; followed by twice-weekly long-term dosing, if required

Isotretinoin is available in 10 mg and 20 mg capsules.

The adverse effects associated with the use of isotretinoin are numerous, but low doses are generally well tolerated. Many patients experience dry skin, lips and eyes. In rare cases isotretinoin may cause hepatic impairment, elevated serum lipid levels, pancreatitis and psychiatric effects including depression and suicide.¹³

Medicines to reduce flushing

Carvedilol, a non-selective beta-blocker with some alpha-blocking activity may be prescribed to reduce flushing as an unapproved indication.¹ A suggested treatment regimen is:²¹

- Carvedilol, 6.25 mg, twice daily

Carvedilol is contraindicated in patients with asthma, hypotension or bradycardia; for a full list of contraindications see the New Zealand Formulary (NZF).

Clonidine, an alpha₂-receptor agonist, may be prescribed to patients with rosacea to reduce flushing as an unapproved

indication.¹ Low doses of clonidine are recommended:²²

- Clonidine, 25 – 50 micrograms daily

Clonidine is contraindicated in patients with severe bradyarrhythmia; for a full list of contraindications see the NZF. Clonidine should be withdrawn gradually to prevent rebound hypertension.¹³

Calcineurin inhibitors, including tacrolimus ointment and pimecrolimus cream, may provide some reduction in inflammation for patients with rosacea.¹

Pharmacological treatment for ocular rosacea

Pharmacological treatment for ocular rosacea may be considered after non-pharmacological treatments have been trialled. Encourage patients to continue to practice good lid hygiene and use ocular lubricants. Oral tetracyclines, e.g. doxycycline, and macrolides, e.g. erythromycin, typically for one to three months, may improve tear film stability and normalise meibomian secretions in patients with ocular rosacea.¹⁰

General practitioners are recommended to discuss patients with severe ocular rosacea with an ophthalmologist. Topical corticosteroids are sometimes cautiously used for the short-term treatment of severe inflammation or rosacea keratitis, however, the long-term use of this medicine increases the risk of glaucoma and cataracts.¹⁰

Specialised treatments for rosacea

Patients with persistent telangiectasia may be treated with vascular laser or intense pulsed light treatment;¹ which may reduce erythema and flushing. If these techniques are unavailable, cautery, diathermy (electrosurgery) or sclerotherapy (saline injections) may be beneficial.¹ A dermatologist will be able to advise patients on what services are locally accessible.

Surgery or carbon dioxide laser may be used by dermatologic or plastic surgeons to reshape the nose of patients with rhinophyma.¹

Acknowledgement: Thank you to **Dr Amanda Oakley**, Honorary Associate Professor, Waikato Clinical Campus, University of Auckland, and Dermatologist, Waikato District Health Board for expert review of this article.

References

1. DermNet NZ. Rosacea. 2014. Available from: <http://dermnetnz.org/acne/rosacea.html> (Accessed May, 2016).
2. Tan J, Berg M. Rosacea: current state of epidemiology. *J Am Acad Dermatol* 2013;69:527-35. doi:10.1016/j.jaad.2013.04.043
3. Spoendlin J, Voegel JJ, Jick SS, et al. A study on the epidemiology of rosacea in the U.K. *Br J Dermatol* 2012;167:598-605. doi:10.1111/j.1365-2133.2012.11037.x
4. Al-Dabagh A, Davis SA, McMichael AJ, et al. Rosacea in skin of color: not a rare diagnosis. *Dermatol Online J* 2014;20.
5. van Zuuren EJ, Fedorowicz Z, Carter B, et al. Interventions for rosacea. *Cochrane Database Syst Rev* 2015;4:CD003262. doi:10.1002/14651858.CD003262.pub5
6. Two AM, Wu W, Gallo RL, et al. Rosacea: part I. Introduction, categorization, histology, pathogenesis, and risk factors. *J Am Acad Dermatol* 2015;72:749-758-760. doi:10.1016/j.jaad.2014.08.028
7. Egeberg A, Hansen PR, Gislason GH, et al. Exploring the Association Between Rosacea and Parkinson Disease: A Danish Nationwide Cohort Study. *JAMA Neurol* 2016; [Epub ahead of print]. doi:10.1001/jamaneurol.2016.0022
8. DermNet NZ. H. pylori infection and skin diseases. 2014. Available from: www.dermnetnz.org/bacterial/h-pylori.html (Accessed Apr, 2016)
9. Moustafa F, Lewallen RS, Feldman SR. The psychological impact of rosacea and the influence of current management options. *J Am Acad Dermatol* 2014;71:973-80. doi:10.1016/j.jaad.2014.05.036
10. DermNet NZ. Ocular rosacea. 2015. Available from: <http://dermnetnz.org/acne/ocular-rosacea.html> (Accessed May, 2016).
11. Two AM, Wu W, Gallo RL, et al. Rosacea: part II. Topical and systemic therapies in the treatment of rosacea. *J Am Acad Dermatol* 2015;72:761-770-772. doi:10.1016/j.jaad.2014.08.027
12. Abram K, Silm H, Maaroo H-I, et al. Risk factors associated with rosacea. *J Eur Acad Dermatol Venereol J EADV* 2010;24:565-71. doi:10.1111/j.1468-3083.2009.03472.x
13. New Zealand Formulary (NZF). NZF v47. 2015. Available from: www.nzf.org.nz (Accessed May, 2016)
14. van Zuuren EJ, Kramer SF, Carter BR, et al. Effective and evidence-based management strategies for rosacea: summary of a Cochrane systematic review. *Br J Dermatol* 2011;165:760-81. doi:10.1111/j.1365-2133.2011.10473.x
15. Thiboutot DM, Fleischer AB, Del Rosso JQ, et al. Azelaic acid 15% gel once daily versus twice daily in papulopustular rosacea. *J Drugs Dermatol JDD* 2008;7:541-6.
16. Di Caprio R, Lembo S, Di Costanzo L, et al. Anti-inflammatory properties of low and high doxycycline doses: an in vitro study. *Mediators Inflamm* 2015;2015:329418. doi:10.1155/2015/329418
17. New Zealand Formulary (NZF). Doxycycline. 2014. Available from: www.nzf.org.nz/nzf/resource/PILs/doxycycline.final.pdf (Accessed Apr, 2016)
18. Park H, Del Rosso JQ. Use of oral isotretinoin in the management of rosacea. *J Clin Aesthetic Dermatol* 2011;4:54-61.
19. Gollnick H, Blume-Peytavi U, Szabó EL, et al. Systemic isotretinoin in the treatment of rosacea - doxycycline- and placebo-controlled, randomized clinical study. *J Dtsch Dermatol Ges* 2010;8:505-15. doi:10.1111/j.1610-0387.2010.07345.x
20. Mylan New Zealand Ltd. New Zealand data sheet. 2015. Available from: www.medsafe.govt.nz/profs/datasheet/i/isotanecap.pdf (Accessed Apr, 2016)
21. Hsu C-C, Lee JY-Y. Carvedilol for the treatment of refractory facial flushing and persistent erythema of rosacea. *Arch Dermatol* 2011;147:1258-60. doi:10.1001/archdermatol.2011.204
22. Rebora A. The management of rosacea. *Am J Clin Dermatol* 2002;3:489-96.