




# **Vulvovaginal health** in post-menopausal women

*Age-related changes in women can result in an increased occurrence of vulvovaginal dermatological conditions such as vulval dermatitis and lichen sclerosus, along with associated issues such as incontinence, recurrent urinary tract infection and sexual dysfunction. Atrophic changes during and after menopause due to declining oestrogen levels can result in a range of symptoms, including vaginal dryness and irritation as well as increase susceptibility to vulvovaginal trauma and infection.*

## Vulvovaginal changes after menopause

### Vulvovaginal atrophy occurs due to decreasing oestrogen levels

Oestrogen is the primary hormone that regulates the physiology of the vulvovaginal tissues. As a woman ages, the progressive decline in circulating oestradiol, beginning in the peri-menopausal period, results in a number of changes that can affect the health of the genitourinary tract. The inherent sensitivity of the vulvovaginal skin, progressive oestrogen deficiency and the close proximity of the urethral opening and the anus, combined with skin changes due to ageing make conditions affecting the vulvovaginal skin common and a cause of distress for many post-menopausal women.

 For further information, see: "Skin and the biology of ageing", Page 14.

Changes that occur with increasing age and decreasing oestrogen levels include:<sup>1</sup>

- Atrophy of vulval tissues – thinning of the skin, atrophy of subcutaneous fat, decreased hair growth
- Atrophy of the vagina – narrowing and shortening of the vagina with constriction of the introitus. The lining of the vagina tends to become thinner, less elastic and smoother due to a decrease in the rugal folds
- Atrophy of all other oestrogen-dependent tissues, e.g. pelvic floor muscles, urethral mucosa, uterus, ovaries
- Decreased vascularity
- Decreased vaginal secretions
- Alterations in the vaginal microflora – decreased glycogen from vaginal epithelial cells results in a change in the pH of the vagina from acidic to more basic (typically > 5.0). The change in pH is detrimental to the survival of acid-producing bacteria (e.g. lactobacilli) and can lead to further alterations in the pH and the microflora.

Vulvovaginal atrophy is the term used to describe the specific atrophic changes of the vulva and vagina that occurs progressively in all women after menopause. It is also regarded as a condition in itself because the characteristic changes due to declining oestrogen can result in a range of symptoms, such as vaginal dryness, irritation and discomfort (Page 18). The atrophic changes also make the vulvovaginal skin more vulnerable to trauma and infection.<sup>1</sup>

### Other vulvovaginal conditions become more common after menopause

In addition to vulvovaginal atrophy, a number of other conditions become more common after menopause, such as vulval dermatitis, lichen sclerosus and less frequently, lichen planus (Page 22). Lichen simplex may also occur in post-menopausal women, however, it is more frequently observed in younger women. The pattern of symptoms from these conditions can often be similar, with the majority of women having itch as their primary symptom. The non-specific nature of the presenting symptoms, however, can make distinguishing between the various conditions difficult.

In some women, more than one vulval condition may be present simultaneously or there may be a more generalised underlying dermatological condition, e.g. psoriasis. Itching from a primary dermatosis may lead to scratching and excessive use of hygienic measures, leading to secondary lichen simplex and irritant contact dermatitis. Other diagnoses should be considered, therefore, if an initial treatment regimen has failed to produce an improvement in symptoms.<sup>2</sup> Making a diagnosis can be difficult in some patients, so it is generally recommended that referral to a Dermatologist or a Gynaecologist (preferably with a special interest in vulval dermatoses) should be considered for confirmation of a diagnosis if the vulval disorder has failed to respond to initial treatment.

Atrophy of oestrogen-dependent tissues can contribute to other gynaecological problems for women who are post-

menopausal, including uterine prolapse, urinary incontinence (see: "Incontinence is a risk factor for skin lesions", Page 22) and recurrent urinary tract infections (see: "Recurrent UTIs", Page 22).<sup>3</sup> Women who are post-menopausal may also continue to have problems with vulvovaginal candidiasis and bacterial vaginosis.

For various reasons, sexually transmitted infections (STIs) are often not considered as a diagnosis in older women.<sup>4</sup> However, many post-menopausal women remain sexually active and may have a higher risk of STIs due to increased susceptibility to infection (as a result of atrophic change) and a lack of condom use, particularly in women who are "newly single".<sup>4,5</sup> Women may also have concerns about sexual function, as this can be affected by vulvovaginal atrophy and vulval skin conditions (see: "Sexual health for older women", Page 25).

### Ask about vulvovaginal health

Many women may be reluctant to talk about vulval or vaginal problems with a health professional and may initially use over the counter products in an attempt to relieve vulvovaginal symptoms. It is estimated that only 25–50% of women with vulvovaginal symptoms seek help from their General Practitioner.<sup>1,6</sup> Research has shown that there are many reasons why women do not ask for help including:<sup>6</sup>

- The feeling that it is an embarrassing, uncomfortable or private matter
- The belief that it is a normal part of getting older
- Not being aware that there are treatments available
- Not knowing how to initiate a conversation about these issues

Acknowledging that changes in vulvovaginal health are an expected part of ageing and initiating a conversation about the presence of any symptoms may encourage women to share their concerns and be more receptive about the options for treatment.<sup>6</sup> Some women may not reveal that they have a skin disorder affecting the vulva because they are uncomfortable or embarrassed by the need for a clinical examination of the vulvovaginal area. Their concerns should be acknowledged and if appropriate, other options could be offered, e.g. seeing a female General Practitioner in the practice if their regular General Practitioner is male.

## The management of common vulvovaginal conditions in post-menopausal women

### Vulvovaginal atrophy

Symptoms of vulvovaginal atrophy include irritation, vaginal dryness, dysuria and other urinary symptoms, dyspareunia and abnormal vaginal discharge.<sup>1</sup> Atrophic vaginitis is the term often used when inflammation accompanies atrophic change, resulting in patchy redness and tenderness of the vaginal introitus.<sup>1</sup> In a woman with vulvovaginal atrophy without inflammation, the tissues tend to be thin, pale and dry. Fissuring of the posterior fourchette (the fold of skin forming the posterior margin of the vagina) is often seen and may also occur as a result of even minimal stretching during vulval or vaginal examination.

Local oestrogen treatment is usually the preferred treatment option, rather than oral or transdermal oestrogen treatment, when the sole aim of treatment is the relief of vulvovaginal symptoms.<sup>6</sup> Treatment with topical oestrogens (e.g. estriol 0.1% cream or 500 microgram pessaries) is regarded as safe and effective.<sup>2</sup> The initial advice should be to use one application or pessary daily in the evening until there is improvement in symptoms (often two – three weeks) and then to reduce the frequency to one evening, twice a week.<sup>1,6</sup> The use of progestogens for endometrial protection is not usually necessary when using topical oestrogens.<sup>1</sup> Patients with vaginitis should be warned that initially the use of oestrogen cream or pessaries may cause stinging or burning, but that this should improve within approximately two weeks. A non-oestrogen containing vaginal moisturising bioadhesive gel, e.g. Replens (unsubsidised), may be used in conjunction with a topical oestrogen but it is less effective at relieving symptoms on its own. A water-based vaginal lubricant may be required to alleviate vaginal dryness and friction-related trauma during sexual intercourse, however, lubricants may also cause transient stinging or burning if the woman has vaginitis or fissuring.<sup>1</sup>

### Uterovaginal prolapse (pelvic organ prolapse)

Women who are peri- or post-menopausal may present with symptoms due to pelvic organ prolapse. The symptoms include a dragging sensation in the pelvis, urinary incontinence or difficulties with micturition and defaecation. Examination will usually reveal bulging of the vaginal walls due to prolapse of the uterus, rectum or bladder and in some women descent of the cervix (or vaginal vault in women following hysterectomy) that depending on the stage of the prolapse may extend through the introitus with straining. Treatment options include pelvic floor exercises (often guided by a physiotherapist), topical oestrogen, use of a vaginal ring pessary or surgery.

## Vulval dermatitis

Vulval dermatitis in post-menopausal women is more likely to be contact dermatitis due to exposure to an irritant such as soap, fragrance, over-washing or urine, than to be atopic dermatitis.<sup>2</sup> Irritants produce inflammation of the skin, which is often aggravated by vulvovaginal atrophy, and cause itch, burning or non-specific irritation. The clinical findings on examination may vary – a woman with mild dermatitis may have redness, swelling and scaling of the affected area, whereas a woman with more severe dermatitis may have skin that is markedly red and swollen with obvious erosions or ulceration.<sup>7</sup> Women with chronic dermatitis can develop lichenification (see: Lichen simplex, below).

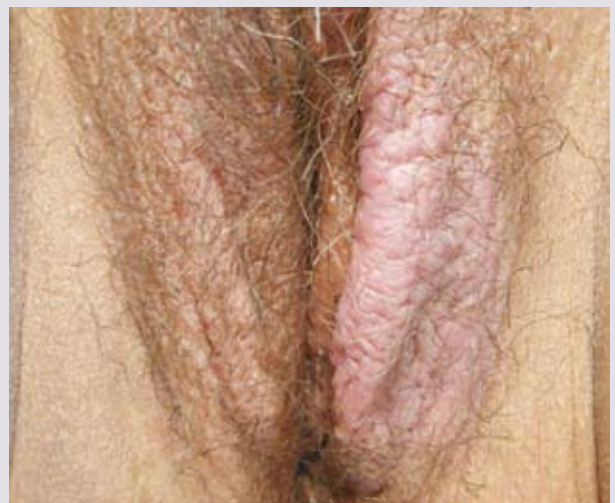Initial management relies on the avoidance of contact with irritants (see: “Strategies to reduce vulvovaginal irritation”, Page 20) and the use of emollients.<sup>7</sup> Low-potency topical corticosteroids, e.g. 1% hydrocortisone, can be trialled to reduce inflammation. In women with severe itch, an oral sedating antihistamine or tricyclic antidepressant may be required at night.<sup>7</sup> Vaginal swabs are appropriate if there is abnormal discharge or malodour, as there may be co-existing infections or symptomatic bacterial vaginosis that should be treated appropriately. The use of topical oestrogen can increase the incidence of *Candida albicans* vaginitis, which is otherwise uncommon in post-menopausal women.

## Lichen simplex

Lichen simplex arises as a result of excessive scratching and rubbing of an area affected with an underlying condition, e.g. contact dermatitis or neuropathic pruritus. This leads to lichenification of hair-bearing skin, usually on the labia majora or perineum, where the skin becomes thickened with increased skin markings and follicular prominence (Figure 1). Lichen simplex is itself intensely itchy, therefore excoriations and broken off hairs are also frequently seen. Pruritus results in a characteristic itch-scratch-itch cycle with symptoms often worse at night or aggravated by heat, humidity, soaps or the presence of urine or faeces on the affected areas.<sup>8</sup> In addition to itch, sometimes women describe a feeling of burning or pain. Symptoms can be intermittent or persistent and the history may extend back for months or years.<sup>8</sup> Lichen simplex can occur anywhere on the body but the vulval area is one of a number of sites more commonly affected, others being the lower legs, forearms, wrists and the back of the scalp and neck.<sup>9</sup> On the vulva, lichen simplex can be localised to one area or widespread, although mucosal or glabrous (hairless) areas are not affected.<sup>8</sup>

Management, which aims to reduce itch and allow healing, involves a number of steps, along with advice on vulval care (see: “Strategies to reduce vulvovaginal irritation”, Page 20). The steps are to:<sup>9,10</sup>

- Identify and manage the condition that has produced the primary itch, e.g. dermatitis from an irritant or allergen, lichen sclerosis (see below). Neuropathic pruritus due to pudendal nerve entrapment or radiculopathy may explain symptoms if a primary dermatosis cannot be identified.
- Prescribe a sedating oral antihistamine or low-dose tricyclic antidepressant at night to break the itch-scratch-itch cycle and to assist with sleep
- Prescribe a potent topical corticosteroid (e.g. betamethasone valerate ointment) to be applied once daily to thickened skin to reduce lichenification. Reduce the potency or frequency of the topical corticosteroid as the plaques resolve, usually after four to six weeks depending on the extent and severity of lichen simplex. If treatment with betamethasone valerate ointment does not appear to be beneficial then referral to a Dermatologist is recommended. Ultra-potent topical corticosteroids such as clobetasol propionate ointment can be used but should ideally be prescribed only for specific indications when a diagnosis has been confirmed, and their use should be monitored.
- Explain how and where to apply the ointment; application of potent topical corticosteroids on non-affected skin risks steroid-induced cutaneous atrophy



**Figure 1:** Lichen simplex showing asymmetrical lichenification of labia majora. Image provided by DermNetNZ

## Strategies to reduce vulvovaginal irritation

Eliminating any aggravating factors is an important step in the management of women with conditions affecting the vulvovaginal area.<sup>8</sup> Aggravating factors include scratching and rubbing, products and routines used for cleansing, exposure to urine or faeces and medicines or products used to reduce symptoms from the underlying condition.<sup>8</sup> Women who are post-menopausal are more likely to be affected by these factors than younger women, as the barrier that the vulvovaginal skin forms is more vulnerable due to oestrogen deficiency.

Women can be advised to:<sup>8</sup>

- Avoid scratching and rubbing if possible – non-pharmacological methods for the relief from itch include cool gel pads, refrigerated petroleum jelly on a pad or cloth, or applied directly to the vulva. Petroleum jelly also acts as a moisturiser and a barrier preparation. It can be applied frequently. Sitting in a lukewarm bath may also be soothing. Advise women to keep their fingernails short or to wear gloves at night.
- Wash the vulva with water and avoid the use of soaps, bubble baths, bath oils and salts or perfumed products.
- Use white, unscented soft toilet paper – some of the inks on the printed papers can irritate skin. Avoid using baby or personal wipes; these wet products have a high-concentration of preservatives (such as methylisothiazolinone) to which contact allergy is increasingly reported.
- Tell their doctor if they have urinary incontinence so that this can be treated. Ensure pads or underwear designed for incontinence are used rather than pads intended for menstrual use. If leakage occurs, ideally the urine should be rinsed off the vulva with water followed by the application of petroleum jelly to provide a barrier.
- Wear comfortable underwear and avoid pantyhose. Avoid wearing underwear at night unless specific incontinence products are required.
- Avoid using over-the-counter products on the genital area, e.g. topical antifungal medicines or douches, as these can cause pain or irritation and may alter normal or desirable vaginal microflora

In addition, cool packs to control itch short-term, and emollients to reduce dryness and itch, can be applied frequently and may be helpful. Erosions and fissures can be caused by scratching and, although uncommon, can predispose the patient to secondary bacterial infections which may require oral antibiotics.<sup>8</sup> Treatment can often result in complete resolution of symptoms, however, this relies heavily on an effective approach to the elimination of vulval irritants and being able to stop the itch-scratch-itch cycle. For some women, lichen simplex can become chronic and cause significant distress. Long-term use of a tricyclic antidepressant, and intermittent applications of topical corticosteroid ointments (e.g., as weekend pulses), may be required in these women.

Follow-up is essential to ensure symptoms are controlled and treatment is used effectively and safely

### Lichen sclerosis

Lichen sclerosis is an inflammatory skin disorder, thought to be of autoimmune origin, but with influences from genes, hormones, irritants and infection.<sup>8,11</sup> It can occur in women of any age, but most frequently in those aged over 50 years.<sup>11</sup> Lichen sclerosis primarily affects the glabrous (hairless) vulval, perineal and perianal skin but does not involve the vagina itself. Longstanding disease can extend to involve the labia majora and inguinal folds. Approximately 10% of women with vulval lichen sclerosis will also have non-genital areas of skin affected,<sup>11</sup> and up to 20% may have another autoimmune disease, such as thyroid dysfunction, vitiligo, psoriasis or pernicious anaemia.<sup>8,11</sup>

The most common symptom in women with lichen sclerosis is severe itch, although many are asymptomatic. Women may also complain of pain, which may be aggravated by the development of fissures secondary to scratching or friction from sexual intercourse. Chronic lichen sclerosis can cause distortion of the genital anatomy, including adhesions, resorption or partial fusion of the labia minora, and narrowing of the vaginal introitus causing dyspareunia compounded by post-menopausal changes from atrophy and loss of elasticity.<sup>8</sup> Scarring and fissure development around the anus can cause pain or bleeding and aggravate constipation.

On examination, the affected areas of skin may appear white and thickened and there may be ecchymoses, petechiae or purpura (Figure 2). Scratching can result in fissures and, rarely, secondary infection.

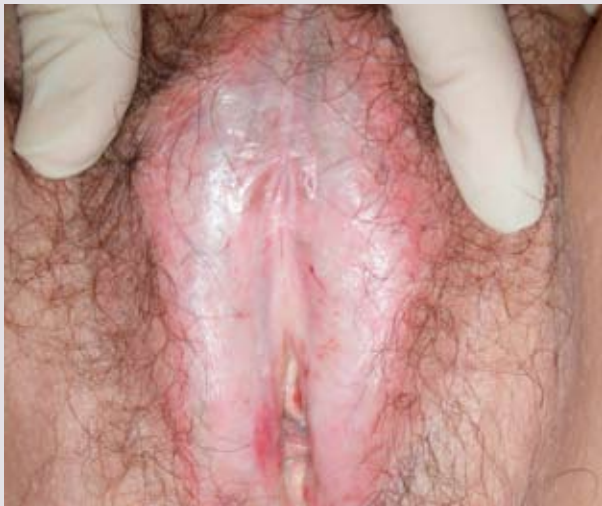Referral to a specialist in vulvovaginal disease (usually a Dermatologist or a Gynaecologist with an interest in vulval

disorders) is recommended for confirmation of the diagnosis and, when management is complex, shared long-term care. It is not always easy to distinguish lichen sclerosus from other conditions affecting the vulval area and a biopsy is often required for an accurate diagnosis. Lichen sclerosus is rarely curable, although can usually be improved, therefore it is important that a long-term plan is established for treatment and follow up.<sup>8</sup> In addition, lichen sclerosus is associated with the development of vulval intraepithelial neoplasia (VIN) and invasive squamous cell carcinoma, with an incidence of approximately 5%.<sup>8</sup> In women with lichen sclerosus, ideally the vulval skin should be reviewed at least annually, or more often if symptoms persist despite treatment, so that an alternative diagnosis can be considered or if malignancy develops it is detected early (see: "Malignant vulval skin lesions", Page 24). Education is essential to explain the long-term nature of the disorder, the need for on-going, at least intermittent, treatment and follow-up.

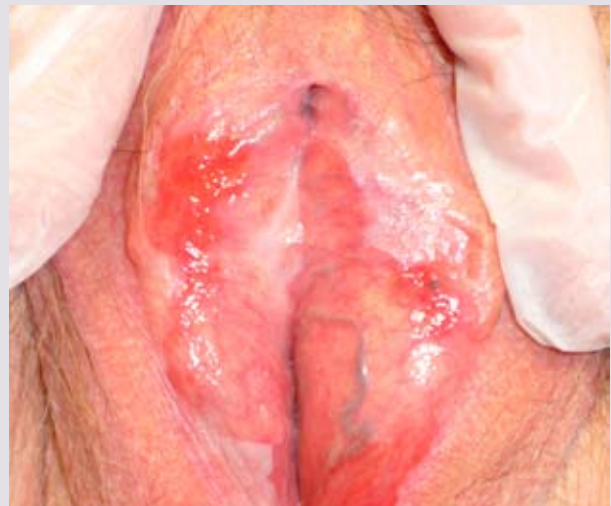Treatment with a potent or ultra-potent topical corticosteroid ointment, e.g. betamethasone valerate ointment or clobetasol propionate applied at night to affected areas for up to three months, is the usual initial choice and is aimed at reducing symptoms to a tolerable level.<sup>8</sup> Ensure that the woman is aware of the specific areas of affected skin that should be treated. The duration of daily treatment depends on the initial severity

and the response to treatment. The frequency of application or potency of the topical corticosteroid should then be slowly reduced once the symptoms have begun to settle, e.g. used one to three times a week. More limited use of a potent or ultra-potent corticosteroid (e.g. a maximum of two weeks) is recommended in women with lichen sclerosus affecting the perianal skin because this is more susceptible to thinning.<sup>8</sup>

The majority of post-menopausal women with vulval lichen sclerosus should also be treated with intravaginal oestrogen cream. The response to corticosteroid treatment can be quite variable, with itch reducing within a few days but the appearance of the skin not returning to normal for weeks or months.<sup>11</sup> Maintenance treatment is required in many women, e.g. a topical corticosteroid used on a weekly basis, to prevent reoccurrence of symptoms and reduce the progression of scarring.<sup>8</sup> If scarring has already occurred, this is not reversible with corticosteroid treatment. If there is narrowing of the vaginal introitus, the use of vaginal dilators can be trialed. These are used progressively, starting with a small size and increasing in size as tolerated. Surgery is sometimes the best treatment option, particularly if the woman experiences difficulties with micturition (due to labial fusion causing obstruction of the urethra) or if the use of vaginal dilators has not resolved problems with sexual intercourse.<sup>8,11</sup>




**Figure 2:** Lichen sclerosus showing whitening of the vulva extending towards the perianal skin with typical distortion, fusion and resorption of labia minora and ecchymosis. Image provided by DermNetNZ



**Figure 3:** Erosive lichen planus showing characteristic redness and erosions of vulvovaginal skin. Image provided by DermNetNZ

## Incontinence is a risk factor for skin lesions

The presence of urine and/or faeces on the skin creates an alkaline pH due to bacteria digesting urea and producing ammonia.<sup>14</sup> This increases the activity of proteases and lipases which can cause skin irritation and dermatitis.<sup>14</sup> Skin breakdown becomes more likely in older women if their skin remains moist for extended periods. Vulvovaginal atrophy, scratching and inappropriate cleansing can exacerbate this problem by further diminishing the skin's barrier function.

 For further information, see: "Urinary incontinence in adults", BPJ 55 (Oct, 2013)

## Recurrent UTIs are more common in older women

Older women are more susceptible to recurrent urinary tract infection (UTI) due to factors such as vulvovaginal atrophy (which increases risk of trauma and infection), incontinence, use of catheters and living in a residential care setting. It is estimated that each year 8% of postmenopausal women will have a UTI and 4% may have recurrent infections.<sup>3</sup>

Asymptomatic bacteriuria is very common in older women and does not require antibiotic treatment (or testing). The diagnosis of UTI in older women should therefore be made based on clinical signs and symptoms, as well as the results of urine culture. Urine culture should be requested in older women who have recurrent infection, or signs of significant infection such as fever > 38°C, worsening urgency or frequency, suprapubic pain, urinary incontinence or gross haematuria.

For some women recurrent urinary tract infections may be prevented by the use of topical oestrogen treatment.<sup>3</sup>

## Lichen planus

Women with vulval lichen planus may present with itch and pain, similar to the symptoms of lichen sclerosus, however, it is less common than lichen sclerosus, is more likely to affect other areas of the body and also affects mucosal skin, e.g. of the vagina and mouth.<sup>12</sup> Lichen planus, like lichen sclerosus is also thought to be an inflammatory skin condition of autoimmune origin. Lichen planus most often affects women from age 30 – 60 years.<sup>10</sup>

The severity of vulval lichen planus tends to vary depending on the subtype. Subtypes include a cutaneous form (purplish or brown papules in hair-bearing areas), a mucosal form (painless, often itchy, white streaks) or the more common erosive form, affecting the vaginal introitus, characterised by marked redness and erosions with a characteristic white hyperkeratotic border (Figure 3).<sup>8, 13</sup> Erosive lichen planus can result in severe distortion and scarring of the affected areas with pain rather than itch being the main symptom.<sup>10, 12</sup> Unlike lichen sclerosus, lichen planus often affects the vaginal mucosa causing a bloody vaginal discharge.

The diagnosis of lichen planus can often be made based on the history and clinical findings, however, it is recommended that women be referred to a specialist in vulvovaginal disease for confirmation of the diagnosis, usually with biopsy although the histopathology may be nonspecific. The histological changes in lichen planus are often subtle and site-dependent with central areas less likely to show classical features than the samples taken from the margins.<sup>13</sup> In addition, as with lichen sclerosus, there is a risk of development of vulval malignancy and the condition can be more challenging to manage.<sup>8, 12, 13</sup>

Initial treatment for lichen planus is the same as for lichen sclerosus, but some women may require oral corticosteroids or immunomodulatory medicines, such as methotrexate, if the use of topical corticosteroids has not improved their symptoms.<sup>10, 12</sup>

## Seborrhoeic dermatitis and psoriasis in post-menopausal women

Although more often diagnosed in younger women, seborrhoeic dermatitis and psoriasis may affect women of any age. These two conditions may occur simultaneously and when they are difficult to distinguish, "sebopsoriasis" may be diagnosed.

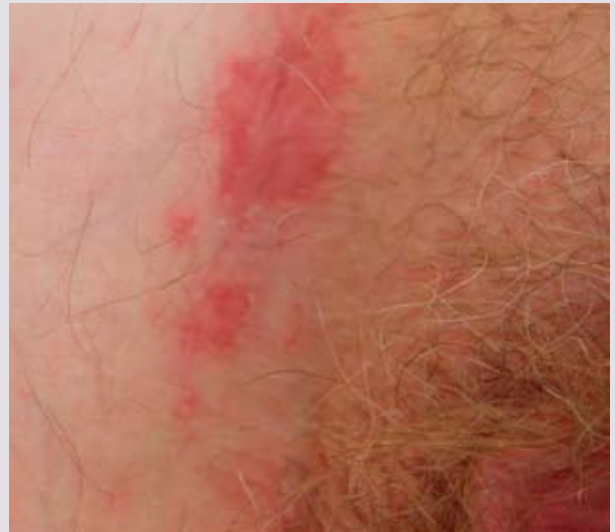Seborrhoeic dermatitis tends to affect skin folds (e.g. inguinal, crural and interlabial creases), and hair-bearing areas (e.g. mons pubis, labia majora, perianal areas) and causes mild symptoms such as itch, scale and fissuring. Most women

with seborrhoeic dermatitis give a history of pityriasis capitis (dandruff) and seborrhoeic dermatitis affecting the scalp, eyebrows, retroauricular and nasolabial folds where they have ill-defined pink, flaking patches. Seborrhoeic dermatitis is treated with intermittent application of a topical antifungal (e.g., ketoconazole shampoo, twice weekly in the shower) and a low-potency topical corticosteroid (e.g., 1 % hydrocortisone cream) when symptomatic. This combination works well for seborrhoeic dermatitis, but is less effective for sebopsoriasis, which may require short term treatment with more potent corticosteroids (see below).

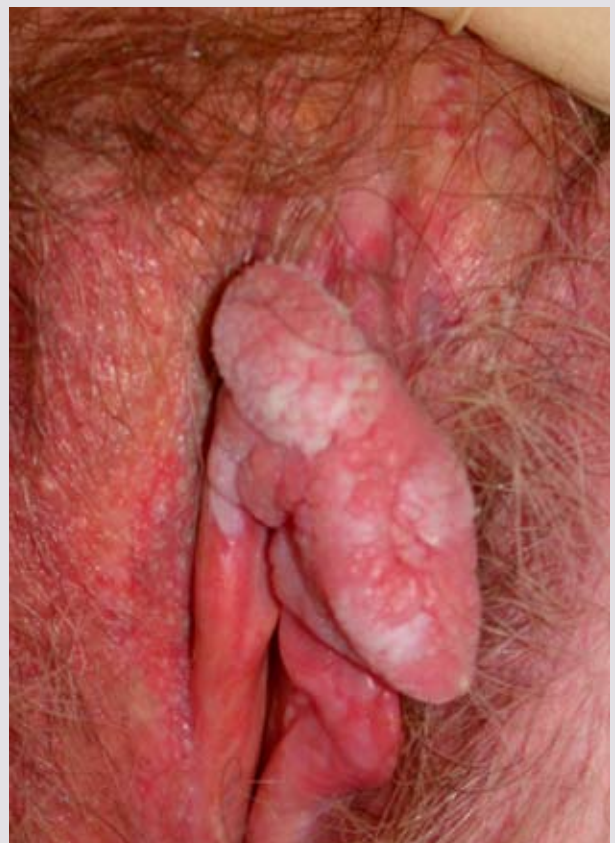Psoriasis affecting the vulvovaginal area can be part of a more widespread type of psoriasis (usually plaque psoriasis), however, in 2 – 5% of patients, it may affect the genital area only.<sup>15,16</sup> Women with psoriasis of the vulvovaginal area often present with well-circumscribed, bright red plaques that are symmetrically distributed in the vulva.<sup>15</sup> Other flexural sites are also commonly affected, e.g. natal cleft, umbilicus, axillae and under the breasts or an abdominal apron (if the flexures are involved it is referred to as flexural psoriasis).<sup>16</sup> Itch can vary from minimal to severe. On examination, scale can be a prominent feature, but it is often absent in moist areas resulting in a shiny smooth appearance to the affected skin (Figure 4). Psoriasis can be colonised by bacteria and yeasts, leading to symptomatic maceration and fissuring.

Treatment is usually with intermittent courses of low to moderate potency topical corticosteroids.<sup>15</sup> Flexural psoriasis usually responds well to the use of topical corticosteroids, however, it is often recurrent and may require repeated but intermittent use of a topical corticosteroid.<sup>16</sup> Education is therefore essential to explain to women that psoriasis tends to recur or that it may persist and to ensure that they use topical corticosteroids safely. Topical corticosteroids are absorbed to an increased extent by genital skin and this can result in thinning of the skin.<sup>15</sup> The use of more potent topical corticosteroids should be limited to a few weeks only and stepped down to a less potent corticosteroid once the psoriasis is improving.<sup>15</sup>

Stronger topical treatments used for psoriasis affecting other parts of the body (e.g. dithranol cream, coal tar preparations) may be too irritating for use in the vulvovaginal area, although they can be used for short periods and washed off or diluted in an emollient.<sup>15</sup> Oral medicines (e.g. methotrexate) are usually not required for psoriasis that is limited to the genital area, and the use of phototherapy should be avoided.<sup>15</sup>



**Figure 4:** Sebopsoriasis in skin flexure showing red shiny skin with an absence of scale. Image provided by DermNetNZ



**Figure 5:** Squamous cell carcinoma (SCC) affecting the labia minora. SCC are variable in appearance, e.g. they can be warty, fleshy or ulcerated. Image provided by DermNetNZ

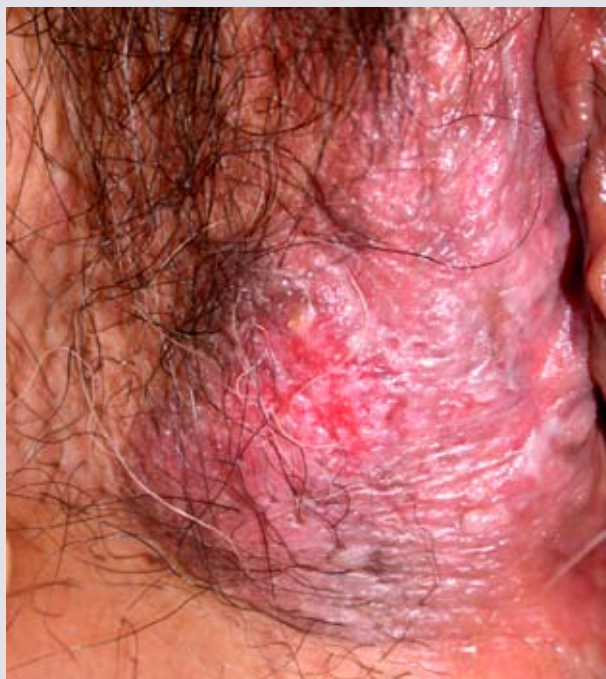

## Less common vulvovaginal conditions in post-menopausal women

### Mucous membrane pemphigoid (or cicatricial pemphigoid)

This is a rare autoimmune disease that causes blistering of mucous membranes, e.g. of the mouth, eye, nose and vulva.<sup>17</sup> It usually affects older people (age > 70 years) and is more common in women.<sup>17</sup> When it involves the vulva it can cause severe scarring resulting in distortion of the vulval anatomy.<sup>18</sup> Clinically it may be difficult to distinguish from other conditions affecting the vulva, such as lichen sclerosus or erosive lichen planus. Referral to a vulvovaginal specialist is recommended for an accurate diagnosis because although mucous membrane pemphigoid can respond to a potent topical corticosteroid it is often a very difficult condition to treat successfully and requires oral corticosteroids or an immunosuppressant medicine.<sup>17</sup>

**Pemphigus vulgaris** is another blistering autoimmune disease that can affect the genital area although more commonly the oral mucosa. Vulval pemphigus is extremely rare in New Zealand.



**Figure 6:** Paget disease of the vulva showing characteristic red thickened (fleshy) appearance. Image provided by DermNetNZ

### Malignant vulval skin lesions

Most malignancies involving the vulval area occur in post-menopausal women, although vulval intraepithelial neoplasia (VIN) may begin prior to menopause and is occasionally diagnosed in younger pre-menopausal women.<sup>19</sup> VIN has the potential to progress to invasive carcinoma of the vulva and women with suspicious lesions require referral to secondary or tertiary care for biopsy and treatment. Approximately 90% of vulval cancers are squamous cell carcinomas (Figure 5), however, other types of malignant lesion may occur in the vulval area including, melanoma, basal cell carcinoma, sarcoma and rarely, Paget disease of the vulva (below) and adenocarcinoma of the Bartholin gland.<sup>20</sup>

Compared to benign dermatoses, malignant lesions are usually asymmetrical, unifocal or multifocal papules, plaques, erosions and ulcers. As with malignant lesions elsewhere on the body, those on the vulva typically have an irregular shape, structure, colour and distribution. Most vulval cancer starts in glabrous or mucosal sites rather than in cutaneous areas.<sup>20</sup> Many women with malignant lesions of the vulva do not present with an obvious mass. Symptoms of vulval cancer vary with the extent and the specific type of cancer involved. For example, itch or pain are associated with squamous cell carcinoma in approximately 50% of women, lesions due to Paget disease of the vulva may cause a burning sensation and itch, while other women with malignant lesions may be asymptomatic.<sup>20</sup> Women with symptomatic vulval invasive cancers may present with itch, an obvious lump, pain, ulceration or bleeding.

Women with suspicious lesions or those that have not responded to treatment for conditions, such as lichen sclerosus should be referred urgently to a specialist for examination, biopsy and further investigations as appropriate. Risk factors for vulval cancer include smoking, VIN, lichen sclerosus, lichen planus, cervical cancer or intraepithelial neoplasia, previous HPV infection and positive HIV status.<sup>20</sup> Vaginal or anal intraepithelial neoplasia (VAIN, AIN) or invasive cancer of the vagina and anus are less common than vulval malignancy.

### Paget disease of the vulva

Paget disease of the vulva (also referred to as extramammary Paget disease) is a rare malignant condition, primarily affecting older women, that can be difficult to distinguish clinically from other skin conditions affecting the vulva.<sup>21</sup> The clinical features include itch and sometimes pain arising from thickened areas of skin around the vulva that become red, scaly and crusted (Figure 6). Typically, the skin lesions will have been present for some time as initially they are asymptomatic or cause minor irritation only. If Paget disease is suspected,

referral to a vulvovaginal specialist is recommended because an accurate diagnosis relies on the results of a biopsy. Other investigations, e.g. colposcopy or pelvic imaging, are likely to be required because there is an association with other underlying malignancies. For example, Paget disease around the anus is associated with an underlying colorectal cancer in approximately 25 – 35% of people.<sup>21</sup>

Management usually involves surgical excision of the lesion, however, recurrence is common (up to 50%) and further surgery is often required.<sup>10, 21</sup> Mohs micrographic surgery is the preferred option, if it is available, as it is associated with lower rates of recurrence and less extensive surgical excision.<sup>10, 21</sup> Non-surgical treatments include the use of laser ablation, topical fluorouracil, imiquimod or photodynamic treatment.<sup>10, 21</sup>

### Benign skin lesions

A number of benign skin lesions may be found in the vulvovaginal area including:

**Seborrheic keratoses:** appear as “stuck on” warty papules on hair-bearing skin. They are benign but may be symptomatic or confused with malignant lesions. Removal (e.g. shave/curette/diathermy or cryotherapy) is generally only indicated if the lesions are painful, increasing in size or to rule out malignancy (excisional biopsy).


**Skin tags** (acrochordon, soft fibroma): appear as pendulous lesions on a narrow stalk. More common in areas of friction (medial thighs), and in women who are obese. Removal by shave excision or cryotherapy is only necessary if painful irritation or inflammation occurs.

**Epidermal inclusion cysts:** are common on the hair-bearing skin of the labia majora. Treatment is only required if the cyst becomes infected (with incision and drainage, and an oral antibiotic if appropriate) or if the cyst is large and symptomatic when surgical excision is usually required, provided any infection has settled.

**Melanocytic naevi** (moles): typically appear as skin- to dark-coloured, soft macules or papules. They are mostly under 6 mm in diameter, and uniform in shape, colour and structure. However, naevi that are larger, irregular in shape or colour are not uncommon in pubic or genital sites. Examine the patient’s overall pattern of naevi to determine whether a particular spot is different from others, i.e. an ugly duckling. If uncertain, arrange dermatoscopic examination by an expert (usually a Dermatologist). Removal is only necessary for cosmetic reasons or to exclude malignancy.

**Angiokeratomas:** are solitary or more often multiple red, purple, blue or blackish papules <5 mm, located on labia majora. Women may present with these lesions because of bleeding or painful thrombosis, or because they are alarmed by the appearance. Reassurance is appropriate. Larger lesions can be distinguished from malignant lesions because of their uniform shape, structure and colour. Dermoscopy reveals single or multiple red, purple or blue clods (lacunes) unless thrombosed, when they are black (and soon resolve).

**Lipomas:** appear as a freely moving, well-defined, sub-cutaneous mass. Excision is only indicated if painful, increasing in size or to exclude malignancy. They are rare in the vulvovaginal region.

 For further information and images of these lesions, see: [www.dermnetnz.org](http://www.dermnetnz.org)

### Sexual health for older women

Questions about sexual health are a routine aspect of general practice. While this is most commonly considered in younger patients, it is important that sexual health is discussed with all patients, regardless of their age. The purpose of a sexual health history is not only to assess risk of sexually transmitted infections, but also to identify problems with sexual function and to assess overall wellbeing and knowledge about sexual health.


Talking about sexual health can be awkward or embarrassing for women of all ages so it is important to ensure that the patient feels comfortable and that the tone of the consultation is appropriate. Consider using an opening statement such as “We routinely discuss sexual health with all our patients, is it ok if I ask you some questions?” This could be followed by more direct questions that can lead into a more detailed discussion about sexual health in older females:


- Are you sexually active?
- Do you have any questions or problems with sex that you would like to discuss?


Sexual response and what is considered normal varies from person to person. In general, a sexual health dysfunction should be only considered a problem if it causes distress to the person or their partner. For example, vaginal dryness or loss of libido may not be an issue for a woman who is not sexually active, however, if the woman meets a new partner, this may be something she seeks help for.

Sexual problems for older women may include:

- Loss of libido; identify any contributing factors such as medicines or unmanaged co-morbidities, offer referral for counselling
- Vaginal discomfort and dryness; recommend use of lubricant or consider use of topical oestrogen
- Vaginal/vulval pain; investigate and treat any cause, recommend use of lubricant, pelvic floor exercises
- Incontinence; manage symptoms and modifiable factors, recommend incontinence wear, pelvic floor exercises
- Effect of co-morbidities and medicines on sexual function; where possible, reduce doses or avoid medicines which decrease libido, e.g. antidepressants, manage co-morbidities
- Lack of privacy, e.g. in a residential care setting; encourage discussion with carers
- Self-esteem issues; encourage discussion and coping strategies, offer referral for counselling
- Relationship issues, e.g. new partner, pressure to have sex; encourage discussion, consider referral for counselling
- Inadequate knowledge about STIs; educate about STIs, testing, appropriate protection and possible symptoms

 The North American Menopause Society has produced a useful resource for women experiencing sexual health issues after menopause, available from: <http://www.menopause.org/for-women/sexual-health-menopause-online>

 General Practitioners with an interest in the area of vulvovaginal health may wish to join the Australian and New Zealand Vulvovaginal Society, which holds an annual conference and update meetings for health professionals. Their website provides a list of specialists with an interest in vulval disorders, information about upcoming meetings and conferences, website links and patient information about vulval disease. See: [www.anzvs.org/index.html](http://www.anzvs.org/index.html)

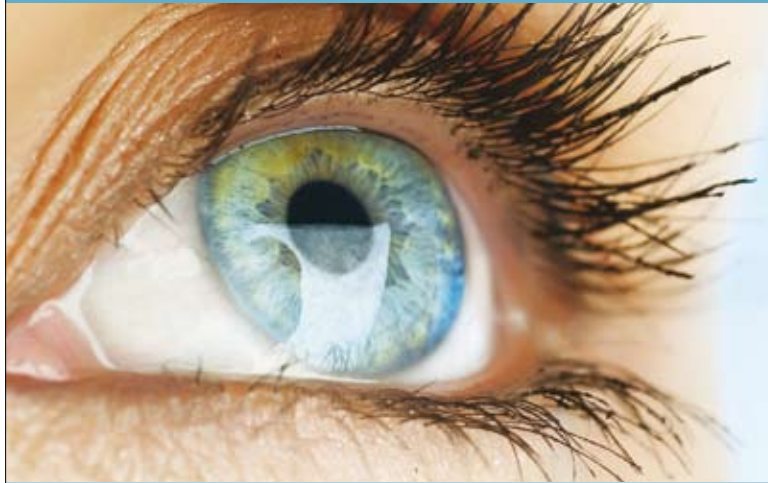 Also see: "Vulvovaginal health in pre-menopausal women", *BPJ* 41 (Dec, 2011).

**ACKNOWLEDGEMENT:** Thank you to **Dr Amanda Oakley**, Specialist Dermatologist, Clinical Associate Professor, Executive Committee member of the Australian and New Zealand Vulvovaginal Society, Tristram Clinic, Hamilton and **Dr Anne Sissons**, Specialist Gynaecologist, Christchurch for expert review of this article.

### References

1. North American Menopause Society. Management of symptomatic vulvovaginal atrophy: 2013 position statement of The North American Menopause Society. *Menopause* 2013;20:888–902.
2. Kingston A. Vulval disease in the postmenopausal patient: a guide to current management. *Menopause Int* 2010;16:117–20.
3. Parish S, Nappi R, Krychman M, et al. Impact of vulvovaginal health on postmenopausal women: a review of surveys on symptoms of vulvovaginal atrophy. *Int J Womens Health* 2013;5:437–47.
4. Drew O, Sherrard J. Sexually transmitted infections in the older woman. *Menopause Int* 2008;14:134–5.
5. Bourne C, Minichiello V. Older people are at risk of sexually transmitted infections. *Australas J Ageing* 2009;28:32–6.
6. Reiter S. Barriers to effective treatment of vaginal atrophy with local estrogen therapy. *Int J Gen Med* 2013;6:153–8.
7. Margesson L. Contact dermatitis of the vulva. *Dermatol Ther* 2004;17:20–7.
8. Thorstensen K, Birenbaum D. Recognition and Management of Vulvar Dermatologic Conditions: Lichen Sclerosus, Lichen Planus, and Lichen Simplex Chronicus. *J Midwifery Womens Health* 2012;57:260–75.
9. DermNet NZ. Lichen simplex. DermNet NZ, 2014. Available from: <http://dermnetnz.org/dermatitis/lichen-simplex.html> (Accessed Aug, 2014).
10. Doyen J, Demoulin S, Delbecq K, et al. Vulvar skin disorders throughout lifetime: about some representative dermatoses. *Biomed Res Int* 2014;[Epub ahead of print].
11. DermNet NZ. Lichen sclerosus. DermNet NZ, 2013. Available from: <http://dermnetnz.org/immune/lichen-sclerosus.html> (Accessed Aug, 2014).

12. DermNet NZ. Lichen planus. DermNet NZ, 2014. Available from: <http://dermnetnz.org/scaly/lichen-planus.html> (Accessed Aug, 2014).
13. Simpson R, Thomas K, Leighton P, et al. Diagnostic criteria for erosive lichen planus affecting the vulva: an international electronic-Delphi consensus exercise. *Br J Dermatol* 2013;169:337-43.
14. Best practice statement: Care of the older person's skin. 2012. Available from: [www.woundsinternational.com/pdf/content\\_10608.pdf](http://www.woundsinternational.com/pdf/content_10608.pdf) (Accessed Aug, 2014).
15. DermNet NZ. Genital psoriasis. DermNet NZ, 2014. Available from: <http://dermnetnz.org/scaly/genital-psoriasis.html> (Accessed Aug, 2014).
16. DermNet NZ. Flexural psoriasis. DermNet NZ, 2013. Available from: <http://www.dermnetnz.org/scaly/flexural-psoriasis.html> (Accessed Aug, 2014).
17. DermNet NZ. Cicatricial pemphigoid. DermNet NZ, 2013. Available from: <http://dermnetnz.org/immune/cicatricial-pemphigoid.html> (Accessed Aug, 2014).
18. Goldstein A, Anhalt G, Klingman D, et al. Mucous membrane pemphigoid of the vulva. *Obstet Gynecol* 2005;105:1188-90.
19. DermNet NZ. Vulval intraepithelial neoplasia. DermNet NZ, 2013. Available from: <http://dermnetnz.org/site-age-specific/vulvar-intraepithelial-neoplasia.html> (Accessed Aug, 2014).
20. DermNet NZ. Vulval cancer. DermNet NZ, 2013. Available from: <http://dermnetnz.org/site-age-specific/vulvar-cancer.html> (Accessed Aug, 2014).
21. DermNet NZ. Extramammary Paget disease. DermNet NZ, 2013. Available from: <http://dermnetnz.org/site-age-specific/extramammary-paget.html> (Accessed Aug, 2014).



## COMMON FORM

The **Common Form** combines features from the Diabetes and CVD modules to produce a streamlined standardised tool that assists in clinical review, disease monitoring and clinical management.

The **Common Form** module features the matching of retinal screening reports to standardised retinal images. The effects of microvascular complications can be visibly demonstrated to patients to facilitate understanding of their condition and as a method to reinforce good glycaemic control.

More information is available at:  
[www.bestpractice.net.nz](http://www.bestpractice.net.nz)



**bestpractice**  
DECISION SUPPORT FOR HEALTH PROFESSIONALS